



Case Report on Multi-Drug Resistance Urosepsis in 19-Year-Old Female

Noor Ul Ain¹, Aqsa Shakoor², Razzia Tehreem², Eman Aftab², Javeria Akhtar¹, Eman Fatima¹, Seerat Iftikhar¹

¹Department of Pharmacology, Government College University Faisalabad, Pakistan

²Department of Pharmacy, The University of Faisalabad, Pakistan

METADATA

Paper history

Received: 20 February 2023

Revised: 21 May 2023

Accepted: 15 August 2023

Published online: 28 September 2023

Corresponding author

Email: ananookhan105@gmail.com

(Noor Ul Ain)

Keywords

Colistin

UTI

MDR

Urine culture

Bacteria

Citation

Noor Ul Ain, Shakoor A, Tehreem R, Aftab E, Akhtar J, Fatima E, Iftikhar S (2023) Case report on multi-drug resistance urosepsis in 19-year-old female. *Innovations in STEAM: Research & Education* 1: 23010201.

<https://doi.org/10.63793/ISRE/0006>

ABSTRACT

Background: Multiple drug resistance (MDR) has emerged as a serious consequence of the overuse of antibiotics. Kidney stone disease results from the formation of crystalline aggregates of urinary solutes within the kidney or urinary tract. In some cases, the stone moves into the ureter, requiring a ureteral stent replacement procedure for management. However, the use of unsterilized equipment during such procedures can lead to urinary tract infections (UTIs).

Objective: This case study highlights the development of MDR *Pseudomonas aeruginosa* following the treatment of a UTI in a patient undergoing ureteral stent replacement.

Method: The patient developed a UTI post-procedure, confirmed through urine culture, which identified *Pseudomonas aeruginosa* as the causative agent. Multiple antibiotics were administered to control the infection.

Results: Despite antibiotic therapy, the patient's condition did not improve. A subsequent urine culture revealed the development of MDR due to the excessive use of antibiotics. Most antibiotics tested showed resistance, with only colistin remaining effective. Treatment with colistin was initiated and continued for 14 days. Follow-up results indicated complete bacterial inhibition and no further infection progression, leading to the patient's stable condition.

Conclusion: This case underscores the importance of rational antibiotic use and proper sterilization techniques to prevent MDR infections, especially in patients undergoing invasive procedures such as ureteral stent placement.

INTRODUCTION

The emergence of multidrug-resistant (MDR) bacterial infections has become a critical global health concern, posing serious challenges to healthcare systems. MDR infections are associated with prolonged hospital stays, increased healthcare costs, and higher mortality rates (Wartu *et al.* 2019). Of particular concern is MDR urosepsis, a life-threatening condition that originates in the urinary tract and spreads into the bloodstream (Porat *et al.* 2023). This condition is difficult to manage due to the resistance of causative bacteria to multiple antibiotics, leaving limited treatment options. Although carbapenems remain the cornerstone of current treatment strategies, their overuse has resulted in growing resistance. Alternative therapeutic options such as beta-lactam/beta-lactamase inhibitor

combinations, ceftiderocol, polymyxins, aminoglycosides, and fosfomycin have been explored as potential treatments (Kunz Coyne *et al.* 2022).

The rise of antibiotic-resistant microorganisms represents one of the greatest threats to modern medicine. The overuse and misuse of antibiotics, combined with the rapid spread of resistance genes among bacterial populations, have significantly contributed to the global burden of MDR infections. Previously, antibiotic-resistant strains were largely confined to nosocomial (hospital-acquired) infections; however, these resistant strains have now become widespread in both community and healthcare settings, infection control measures to prevent the spread of resistant pathogens affecting both Gram-positive and Gram-negative bacterial species (McKinnon *et al.* 2018; Walker *et al.* 2022).

Kidney stone disease, also known as nephrolithiasis or



uroolithiasis, is a common urological disorder characterized by the formation of crystalline aggregates of urinary solutes within the kidney or urinary tract. The pathogenesis, risk factors, and management options for kidney stones vary considerably. They may put a stent into one or both ureters, depending on the reason for the stenting. Allow urine to bypass a kidney stone (renal calculi) that slows or stops urine flow (Guliciuc *et al.* 2021). This stenting procedure prevents development of new blockage after kidney stone treatment. It also prevents blockage from postoperative swelling after the removal of kidney stone. Due to non-stroke instruments used during procedure may lead to MDR urosepsis. It is caused by multidrug-resistant bacteria, is a very serious medical condition where a urinary tract infection (UTI) spreads to the bloodstream. MDR bacteria are resistant to multiple antibiotics, making treatment more challenging and potentially increasing the risk of severe complications like organ failure, sepsis-induced shock, and death. It poses a significant Danger due to the difficulty in finding effective antibiotics to treat the infection. Treatment options may involve using a combination of antibiotics or newer antimicrobial agents. Diagnosis was made in 2107 (7.7%) cases amongst 27,542 patients screened. Microbiological proof of infection was available in 1606 (5.8%) cases. In total, 408 patients had microbiologically proven urosepsis (Petrossillo *et al.* 2020).

Cases were registered from Europe (n: 311–76%), Asia (n: 66–16.1%), Africa (n: 21–5.1%) and USA (n: 10–2.4%). Type of hospital cases were registered from university (n: 228–56%), teaching (n: 107–26%), district (n: 69–17%) and others (n: 4–1%). Mean age of patients with urosepsis was 63 ± 17 years, and the female-to-male ratio was 3:7. An intervention prior to the episode of urosepsis was reported in 324 (79%) cases (clean: n: 77–24%, clean contaminated: n: 99–31%, clean contaminated with bowel segments opened: n: 57–18%, contaminated: n: 28–9%, infected: n: 63–19%, missing: n: 2). A urinary catheter at the time of diagnosis was present in 287 (70%) cases, and urinary tract obstruction was reported in 234 (57%) cases. Urolithiasis was reported in 20% (n: 76, missing n: 21) of cases (Rozwadowski and Gawel 2022).

Given the growing burden of MDR urosepsis, particularly among patients with underlying urological conditions such as kidney stones, there is an urgent need to promote rational antibiotic use and implement stringent.

CASE PRESENTATION

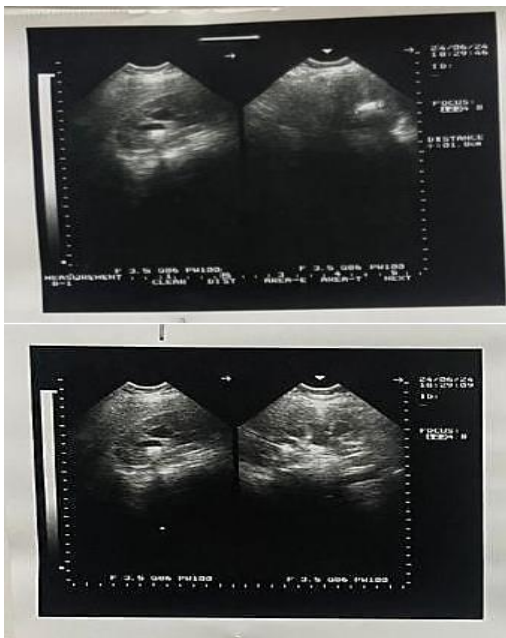
A 20 year old female presented in emergency department of private setup with symptoms of high-grade fever, chill, nausea, vomiting. And difficulty in urinating and from last 3 days there is moderate obstruction in urinating. Also, she had Right flank pain radiating to the groin from last 4 days. Patients' past history has shown that the patient is suffering from kidney stones from the last 4 years. According to the physical examination the patient's blood pressure is 140/90 mmHg, pulse 112 bpm, and body temperature is more than

37.5°C. A ureteral stent was placed to relieve the obstruction of urine and allow the urine to pass from the kidney to the bladder. The stone is removed, and the discomfort of the patient was reduced. But after 3 days of ureteral stent placement the patient had high grade fever, and also have symptoms includes: nausea chill and vomiting. She was again presented to the same setup and was admitted to hospital again due to her severe condition. Empirically she was treated with paracetamol (infusion 1 g/100 mL) and some other antibiotics. After few days when she was not recovered Ultrasound and X-ray imaging examination again perform and show that infection begin in the ureter where the ureter stent placement performs. The reason behind is that during stent placement the equipment are not fully sterilized. So, due to no sterility of the equipment the UTI infection begins. According to the abdominal examination there is tenderness in the right flank and costovertebral angle. Ultrasound and X-ray imaging examinations show that there is a 13mm stone in her right kidney and in left kidney there is 11mmstone at start she was treated with the pain management and hydration. Alpha blockers were prescribed to facilitate the stone passage. The patient was subsequently treated with Cefixime 400 mg, paracetamol (1 g/100 mL infusion), diclofenac, amikacin sulfate, ceftriaxone sodium, meropenem, multivitamins, antiemetics, and moxifloxacin. She showed partial improvement and was discharged home. However, a few months later, she presented it to the emergency department again in a worsened state.

A urine culture was performed, which after 48 h of incubation, identified *Pseudomonas* species (Fig. 1–2). Her condition had significantly deteriorated, and due to the excessive and prolonged use of antibiotics, she had developed multiple drug resistance (MDR). Only a limited number of antibiotics showed susceptibility. Her treatment was adjusted based on the antibiotic susceptibility results, which initially produced some improvement. However, a repeat urine culture revealed that only Colistin remained effective against the isolated bacterial strain. The patient started on colistin, and iron supplementation (Sangobian) was prescribed to support her overall health. Despite this, her condition remained suboptimal.

Investigations

Laboratory investigations confirmed complete resistance to several antibiotics, including Amikacin, Aztreonam, Ciprofloxacin, Imipenem, Meropenem, Ceftazidime, and Levofloxacin. The urine culture indicated that Colistin was the only remaining effective option. To further assess the extent of the infection, a CT-KUB (Kidney, Ureter, and Bladder) scan was performed (Fig 3). The scan revealed the presence of infectious material and pus accumulation, prompting the recommendation for another ureteral stent placement to relieve the obstruction. Additional laboratory results showed a significantly elevated serum parathyroid hormone (PTH) (Fig. 4) level of 649 pg/mL. A parathyroid



RENAL ULTRASOUND

RIGHT KIDNEY:
 . Right kidney shows 13mm stone upper pole .No hydronephrosis is seen.
 Renal cortex & medulla is well appreciated. No cystic disease of the kidney is seen. No signs of back pressure changes noted in the pelvicalyceal system of the kidney.

LEFT KIDNEY.
 Shows 11 mm stone upper pole mild hydronephrosis
 And dilatation of upper ureter.
 Dilated ureter shows 8 mm stone mid and 9 mm stone distal ureter
 Good cortical thickness and CMD.
URINARY BLADDER is full ; no stone or any other abnormality.

Liver . Spleen, Pancreas & Gall Bladder are seen normal.

Fig. 1: Ultrasound reports of renal calculi

Culture And Sensitivity Report

Specimen: *Left DJ Stunt For c/s*

Morphology / Gram's Staining: *Abnops. Negative tools have seen.*

Microorganism Identified: *Pseudomonas species is obtained after 48 hours of incubation at 37°C.*

Catalase Test: *Positive*

Coagulase Test: *Positive*

Oxidase Test: *Positive*

Drugs	Sensitivity	Drugs	Sensitivity
Ampicillin	R	Fosfomicin	S
Amoxycillin	R	Gentamycin	S
Amikacin (Gracil)	S	Gemifloxacin	S
Azithromycin	R	Imipenem	S
Avelox	R	Levofloxacin	S
Augmentin	R	Linzolid	S
Aztreonam	R	Meropenem (Merosol)	S
Cefaclor	R	Nalidixic acid	S
Cefixime	R	Neomycin	S
Cefepime	R	Oxacillin	S
Cefotaxime	R	Piperacillin/Tazobactam	R
Ceftriaxone	R	Terivid	S
Chloramphenicol	R	Septan	R
Ciprofloxacin	R	Sparfloxacin	R
Clindamycin	R	Velosef	R
Ertapenem	S	Zincef	R
Fortum	R	Tetracyclin	R
Erythromycin	R	Urbid	R
Klaxid	R	Vancomycin	R
CBA-150 (Collistin)	S	Vibramycin	R
Sulzone	R	Nitrofurantoin	S
Darpenem	R	Telcoplanin	R
Doxycycline	R	Colistimethate Sodium 1Mlu (Collistin)	S

Specimen: URINE

Culture: Growth obtained after 24 hours of incubation at 37°C.

Isolate1: **Pseudomonas aeruginosa**

Colony Count: 10⁴ - 10⁵ CFU / ML

Pseudomonas aeruginosa	
MIC	Result
B-lactam/B-lactamase Inhibitor Combinations	
Piperacillin-Tazobactam	R
Ceftazidime-Avibactam	R
Cephems & Cephalosporins	
Cefepime	R
Ceftazidime	R
Carbapenems	
Imipenem	R
Meropenem	R
Aminoglycosides	
Amikacin	R
Gentamycin	R
Fluoroquinolones	
Ciprofloxacin	R
Miscellaneous	
Collistin	I

S = Sensitive I = Intermediate R = Resistant MIC = Minimum Inhibitory Concentration (ug/mL)

Fig. 2: Culture report and repeated antibiotic sensitivity for P. aeruginosa

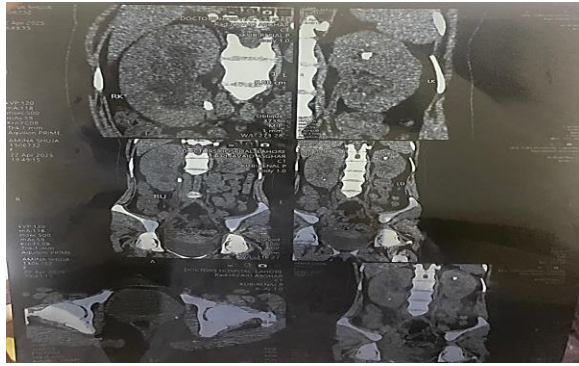


Fig. 3: Report of CT-KUB and serum PTH (649)

Intact PTH.....	649	pg/mL	15-65 pg/mL
Calcium.....	11.1	mg/dL	Adult: 8.4 - 10.2 mg/dL Newborn: 0 - 10 Days: 7.6 - 10.4 mg/dL 10 Days-24 Months: 9 - 11 mg/dL
Troponin-I High Sensitivity.....	2.7	pg/mL	Children: 2-12 years: 8.8 - 10.2 mg/dL Male Upto 34.2 pg/mL Female Upto 15.5 pg/mL

Comments :
 Note :-
 1. $\geq 50\%$ increase in hs Troponin-I result between the first sample and sample after 3 hrs is considered significant.
 2. Studies have shown in general population or patient with stable cardiovascular disease that elevated troponin levels are associated with structural heart disease, risk of future cardiovascular events, and mortality.

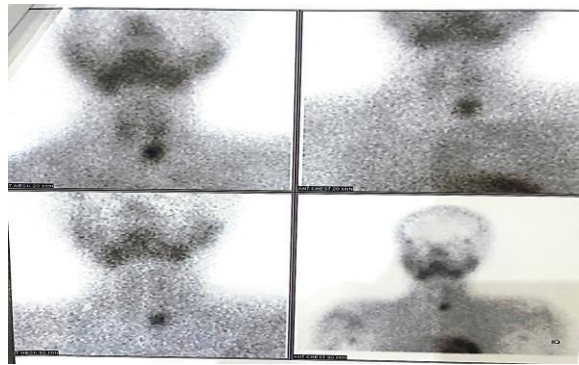


Fig.4: Parathyroid scan

PARATHYROID SCAN

Clinical Features
 Recurrent renal calculi, right sided DJ stent insitu
 Serum PTH= 640 ng/ml
 Parathyroid adenoma??

Procedure
 Parathyroid scanning was done employing Dual Phase 99mTc-MIBI 99mTc-Tetrofosmin scintigraphy. 300 MBq of tracer was injected and anterior static imaging of neck was acquired every 20 minutes till 90 minutes.

Findings
 The early-delayed imaging reveal suspicious area of tracer accumulation/retention in the region of lower pole of left lobe of thyroid gland.
 USG showed iso to hypochoic lesion in the region of lower pole of left lobe of thyroid gland.

Opinion
 Scintigraphic evidence of parathyroid adenoma in the region of lower pole of left lobe of thyroid gland.

Advice

PeST	RESULTS	HISTORY	REFERENCE RANGE
HM23-CBC Diff Profile (CS11)	14/05/25	12/05/25 05/05/25 04/05/25	
WBC Total.....	9960	11740 8100 10100	(4000)µL-10500(µL)
RBC Total.....	5.24	mµL 5.15 4.69 4.30	(3.8 - 5.8)mµL
Hemoglobin.....	13.0	g/dL 12.8 11.9 10.8	12.5 - 18.0g/dL
HCT.....	41.3	% 39.9 36.8 34.0	(37 - 47)%
MCV.....	78.8	fL 77.5 78.5	(78 - 100)fL
MCH.....	24.8	pg 24.9 25.4 25.1	(27 - 31)pg
MCHC.....	31.5	g/dL 32.1 32.3 31.8	(32 - 36)g/dL
Platelet Count.....	336000	µL 392000 598000 631000	(150,000 - 400,000)µL
Neutrophils.....	68	% 65 76 76	(54 - 62)%
Lymphocytes.....	20	% 24 15 16	(25 - 33)%
Monocytes.....	5	% 6 7 7	(1 - 4)%
Eosinophils.....	6	% 5 2 1	(1 - 3)%
Basophils.....	1	% 0 0 0	(0 - 0.75)%
RDW.....	15.7	% 15.4 16.0 15.9	(11.5 - 14.0)%

Fig. 5: Pre-operative CBC reports

TEST	RESULTS	HISTORY	REFERENCE RANGE
Microbiology	19/05/25		
MU01-Urine R/E	YELLOW		Pale Yellow - Yellow
Color.....	Turbid		Clear
Appearance.....	≤ 1.005		1.005 - 1.025
Specific Gravity.....	6.0		5 - 8
pH.....	+++		Negative
Protein.....	Negative		Negative
Glucose.....	Negative		Negative
Ketone.....	Normal		Negative
Urobilinogen.....	Negative		Negative
Bilirubin.....	+++		0 - 2 H-PF
Blood.....	Negative		Negative
Nitrite.....	30-40		Negative
Red Blood Cells.....	+++		Negative
Leukocytes-Estrases.....	1-2		Negative
Epithelial Cells.....	NL		Negative
Yeast.....	NL		Negative
Cast.....	NL		Negative
Crystals.....	NL		Negative
WBC.....	NUMEROUS		1 - 2 H-PF

Fig. 6: Post-operative urine report

Drug	Dose	Frequency	Route	Duration
COLICRAFT (4.5) INJECTION (COLISTIMETHATE-SODIUM)	2 MIU	12 Hourly	INTRAVENOUS	For 7 Day(s)
MYFOL TABLET 400-MCG (L-METHYLFOLATE)	400 MCG	Once a Day	Orally	Continue
PROVAS-N (450+35) TABLET (ORPHENADRINE+PARACETAMOL)	485 MG	12 Hourly (Two times a day)	Orally	For 3 Day(s)
ONDACE (TAB) TABLET 8-MG (ONDANSETRON)	8 MG	12 Hourly (Two times a day)	Orally	Continue
FEFOL-VIT MG CAPSULE 150-MG (FERROUS-SULPHATE+VITS(B1+B2+NIACIN+CYF.A))	150 MG	Once a Day	Orally	Continue
MIMICIPAR TABLET 30-MG (CINACALCET)	30 MG	Once Daily	Orally	Continue
ZOPENT(OPP) TABLET 40-MG (PANTOPRAZOLE)	40 MG	Once Daily	Orally	Continue
MAXFLOW CAPSULE 0.4-MG (TAMSULOSIN)	.4 MG	Before Sleep	Orally	Continue

This prescription is valid till 08-MAY-25

Discharge Instructions :
 1. Diet : AVOID DAIRY PRODUCTS
 2. Activity :AS PER TOLERATED

Fig. 7: Post-operative urine report

Drug	Dose	Frequency	Route	Duration
COLICRAFT (4.5) INJECTION (COLISTIMETHATE-SODIUM)	2 MIU	12 Hourly	INTRAVENOUS	For 7 Day(s)
MYFOL TABLET 400-MCG (L-METHYLFOLATE)	400 MCG	Once a Day	Orally	Continue
PROVAS-N (450+35) TABLET (ORPHENADRINE+PARACETAMOL)	485 MG	12 Hourly (Two times a day)	Orally	For 3 Day(s)
ONDACE (TAB) TABLET 8-MG (ONDANSETRON)	8 MG	12 Hourly (Two times a day)	Orally	Continue
FEFOL-VIT MG CAPSULE 150-MG (FERROUS-SULPHATE+VITS(B1+B2+NIACIN+CYF.A))	150 MG	Once a Day	Orally	Continue
MIMICIPAR TABLET 30-MG (CINACALCET)	30 MG	Once Daily	Orally	Continue
ZOPENT(OPP) TABLET 40-MG (PANTOPRAZOLE)	40 MG	Once Daily	Orally	Continue
MAXFLOW CAPSULE 0.4-MG (TAMSULOSIN)	.4 MG	Before Sleep	Orally	Continue

This prescription is valid till 08-MAY-25

Discharge Instructions :
 1. Diet : AVOID DAIRY PRODUCTS
 2. Activity :AS PER TOLERATED

Fig. 8: Post-operative medications

Urine C/S [Final Report]
GRAM STAIN
CULTURE

No growth after 48 hours of incubation.

Verified On..... : 22-MAY-25 02:02 PM

NATURE OF STAMP.

Fig. 9: Culture report for *Pseudomonas aeruginosa* after medication alteration

scan confirmed parathyroid dysfunction

Treatment

During her hospital stay, the patient received Colistin (2 mg) twice daily for 14 days. Follow-up laboratory tests showed significant improvement, with bacterial growth successfully inhibited. Renal function improved, as reflected by normalization of creatinine levels and estimated glomerular filtration rate (eGFR). Her white blood cell (WBC) count decreased from 17,000 to 9,000. The treatment plan was continued, and based on her laboratory and imaging results, a multidisciplinary approach was adopted. A stepwise treatment protocol was implemented, which included surgical removal of the overactive parathyroid gland, responsible for hypercalcemia and recurrent kidney stone formation. In the same surgical session, laser lithotripsy was performed to remove the kidney stones, both procedures were conducted under a single anesthesia. Following surgery, the patient showed gradual clinical improvement (Fig. 5–9).

DISCUSSION

Multi drug resistance is a sever condition in which the patient develops resistance to the antibiotic because of excessive use. Multidrug resistance (MDR) is a kind of acquired resistance of microorganisms and cancer cells to chemotherapeutic drugs that are characterized by different chemical structures and different mechanisms of action (Linhares *et al.* 2015). Urolithiasis is a disorder that is characterized by the development of solid crystalline aggregates of urinary solutes within the urinary space of the kidney. Her are the number of treatments to treat the kidney stone. For the ureteral obstruction the ureteral stent placement is used now day other procedures are also used to treat ureteral obstruction (Parajuli *et al.* 2017). Here we discuss the case report of a patient who had ureteral obstruction. Ureteral stent placement is used for treatment but due to non-sterile conditions of the equipment's the patient develops Urosepsis. And due to excessive use of the antibiotics the patient develops antibiotic resistance. Patient is badly affected and in critical condition. From this case

presentation we can assure that the effect of colistin has shown to the bacteria without any severe adverse effects leading to a progressive treatment (Babar *et al.* 2021).

Overall, this case illustrates the growing threat of MDR in urological settings and highlights the significance of infection control practices and antibiotic stewardship in preventing such complications.

CONCLUSIONS

This case highlights the serious complications that can arise from inadequate sterilization and excessive antibiotic use, leading to multidrug-resistant urosepsis. Strict aseptic techniques and rational antibiotic use are essential to prevent such infections. Colistin proved effective in managing the MDR infection, demonstrating its potential as a last-resort treatment option in similar cases.

AUTHOR CONTRIBUTIONS

All the authors contributed equally to the write up.

CONFLICTS OF INTEREST

The authors affirm that they possess no conflicts of interest.

DATA AVAILABILITY

Not applicable

ETHICS APPROVAL

Informed consent was obtained from patient.

FUNDING SOURCE

No funding was acquired for this work.

REFERENCES

- Babar ZU, Dodani SK, Nasim A (2021) Treatment outcome and adverse effects of colistin in adult patients with carbapenem-resistant Gram-negative bacteremia from Pakistan. *International Journal of Infectious Diseases* 106: 171–175. <https://doi.org/10.1016/j.ijid.2021.03.004>.
- Guliciuc M, Maier AC, Maier IM, Kraft A, Cucuruzac RR, Marinescu M, Șerban C, Rebegea L, Constantin GB, Firescu D (2021) The urosepsis—a literature review. *Medicina* 57: 872. <https://doi.org/10.3390/medicina57090872>.

- Kunz Coyne AJ, El Ghali A, Holger D, Rebold N, Rybak MJ (2022) Therapeutic strategies for emerging multidrug-resistant *Pseudomonas aeruginosa*. *Infectious Diseases and Therapy* 11: 661–682. <https://doi.org/10.1007/s40121-022-00591-2>.
- Linhares I, Raposo T, Rodrigues A, Almeida A (2015) Incidence and diversity of antimicrobial multidrug resistance profiles of uropathogenic bacteria. *BioMed Research International* 2015: 354084. <https://doi.org/10.1155/2015/354084>.
- McKinnon J, Chowdhury PR, Djordjevic SP (2018) Genomic analysis of multidrug-resistant *Escherichia coli* ST58 causing urosepsis. *International Journal of Antimicrobial Agents* 52: 430–435. <https://doi.org/10.1016/j.ijantimicag.2018.06.017>.
- Parajuli NP, Maharjan P, Parajuli H, Joshi G, Paudel D, Sayami S, Khanal PR (2017) High rates of multidrug resistance among uropathogenic *Escherichia coli* in children and analyses of ESBL producers from Nepal. *Antimicrobial Resistance & Infection Control* 6: 9. <https://doi.org/10.1186/s13756-016-0168-6>.
- Petrosillo N, Granata G, Boyle B, Doyle MM, Pinchera B, Taglietti F (2020) Preventing sepsis development in complicated urinary tract infections. *Expert Review of Anti-infective Therapy* 18: 47–61. <https://doi.org/10.1080/14787210.2020.1700794>.
- Porat A, Bhutta BS, Kesler S (2023) Urosepsis. In: *StatPearls [Internet]*. Treasure Island, FL: StatPearls Publishing. <https://doi.org/10.1186/s13756-016-0168-6>.
- Rozwadowski M, Gawel D (2022) Molecular factors and mechanisms driving multidrug resistance in uropathogenic *Escherichia coli*—an update. *Genes* 13: 1397. <https://doi.org/10.3390/genes13081397>.
- Walker MM, Roberts JA, Rogers BA, Harris PN, Sime FB (2022) Current and emerging treatment options for multidrug resistant *Escherichia coli* urosepsis: A review. *Antibiotics* 11: 1821. <https://doi.org/10.3390/antibiotics11121821>.
- Wartu JR, Butt AQ, Suleiman U, Adeke M, Tayaza FB, Musa BJ, Baba J (2019) Multidrug resistance by microorganisms: A review. *Science World Journal* 14: 49–56.