



CASE REPORT

A Case Report of Non-Classical Congenital Adrenal Hyperplasia of a Two-Year-Old Male Child

Noor Ul Ain, Fakhar Eman, Manahal Amjad
Department of Pharmacy, The University, Faisalabad 38000, Pakistan

METADATA	ABSTRACT
<p>Paper history Received: 20 November 2023 Revised: 25 April 2024 Accepted: 30 October 2024 Published online: 25 November 2024</p> <p>Corresponding author Email: ainnoorul599@gmail.com (Noor Ul Ain)</p> <p>Keywords 21-Hydroxylase deficiency Androgen excess Precocious puberty Hydrocortisone therapy</p> <p>Citation Noor Ul Ain, Eman, F, Amjad M (2024) A case report of non-classical congenital adrenal hyperplasia of a two-year-old male child. <i>Innovations in STEAM: Research & Education</i> 2: 24020205. https://doi.org/10.63793/ISRE/0020</p>	<p>Background: Non-Classical Congenital Adrenal Hyperplasia (NCCAH) is a relatively common autosomal recessive disorder characterized by partial deficiency of 21-hydroxylase enzyme, resulting in excessive adrenal androgen production. The patient history included a high risk of supported pregnancy with growth injections and prior miscarriage.</p> <p>Objective: This case report presents a rare early-onset of NCCAH in a 2-year-old male child who was brought to the endocrinology emergency department with premature pubic hair development and increased penile length. The objective was to find out the cause of this abnormal condition and find a clinical measure to arrest the condition.</p> <p>Methodology: Based on clinical features and biochemical findings, a diagnosis of NCCAH was made. Hormonal therapy with oral hydrocortisone was initiated.</p> <p>Results: Laboratory investigations disclose elevated levels of luteinizing hormones, ACTH, 17-hydroxyprogesterone, progesterone, and testosterone, while other hormonal and imaging studies were within normal range. Hormonal therapy with oral hydrocortisone led to partial improvement in androgen levels over a 3-month follow-up.</p> <p>Conclusion: This case highlighted the need for early recognition of atypical presentation of NCCAH to prevent complications such as precocious puberty, compromised adult height, and fertility issues by timely therapeutic interventions.</p>

INTRODUCTION

Congenital adrenal hyperplasia (CAH) is an autosomal recessive endocrine condition that affects cortisol production. The syndrome is caused by reduced activity of cortisol-producing enzymes, which results in prolonged adrenocorticotrophic hormone (ACTH) stimulation of the adrenal cortex and accumulation of steroid precursors upstream of the enzymatic block (Claahsen-van der Grinten *et al.* 2022). CAH has been separated into classic and non-classic (NC) variants. The current research indicates that polymorphisms in the *CYP21A2* gene and their phenotypic expression are their main cause. In the classic type, enzyme activity is significantly decreased or missing, limiting cortisol production and resulting in newborn symptoms (Claahsen-van der Grinten *et al.* 2022). Non-classic CAH (NCCAH), also known as late-onset CAH, is the most prevalent autosomal recessive endocrine disorder. It is caused by partial

21-hydroxylase activity (about 20–50% of normal), which is adequate to sustain important cortisol and aldosterone activities; thus, hormone replacement is often needed. However, due to low cortisol levels, ACTH secretion is not controlled, resulting in adrenal hyperplasia and hyperandrogenism (Podgórski *et al.* 2018).

Additionally, 21-hydroxylase deficiency accounts for approximately 95% of CAH cases and can present as either the classic (salt-wasting or simple virilizing) or non-classic phenotypes. The remaining cases are primarily caused by 11 β -hydroxylase or 3 β -hydroxysteroid dehydrogenase deficits, in both classic and non-classic forms. In rare cases, defects in 17 α -hydroxylase/17,20-lyase or cholesterol desmolase can lead to serious clinical problems (Piróg *et al.* 2024).

Mutations in *CYP21A2* range from complete loss to partial retention of enzyme function, with the majority resulting from gene conversion events between the functional gene (*CYP21A2*) and its highly similar pseudogene



(*CYP21A1P*). Functional testing show residual activity of 0–5% in severe mutations (Adriaansen *et al.* 2022). According to Kurtoğlu and Hatipoğlu (2017), classical CAH affects 1 in every 15,000–20,000 live births, while NCCAH affects 1 in 200 Caucasians and 1 in 100 of the general population.

The disease is more prevalent among Ashkenazi Jews (1 in 27), Hispanics (~1 in 40), Slavs (1 in 50), and Italians (1 in 300) (Macut *et al.* 2019). According to the original clinical criteria, NCCAH symptoms develop after the age of five years. Females are born without genital ambiguity, but both sexes can develop indications of androgen excess at any time throughout postnatal life. Delayed menarche is prevalent in adolescent females, and secondary amenorrhea can occur in young women (Auer *et al.* 2023).

Female patients may also experience hirsutism, oligomenorrhea, or polycystic ovary, while afflicted males may infrequently present with oligospermia. Untreated people of both sexes may develop small adult height, insulin resistance, and impaired fertility. Boys frequently experience premature pubertal development, precocious puberty, acne, and fast growth. Laboratory results frequently show elevated 17-hydroxyprogesterone, increased ACTH, and excessive luteinizing hormone (LH) release. Genetic testing is recommended for all CAH patients, including parents and siblings. NCCAH patients had an increased risk of testicular adrenal rest tumors, cardiovascular morbidity, and infertility (Muthusamy *et al.* 2010). The treatment of 21-hydroxylase deficiency began in the 1950s. Glucocorticoid replacement therapy restores insufficient cortisol while suppressing excess ACTH, lowering adrenal androgen synthesis. Hydrocortisone is the ideal replacement for 21-OHD, 11 β -OHD, and 17 α -hydroxylase deficits due to its favorable physiologic profile and lower risk of side effects (Muthusamy *et al.* 2010). The treatment of 21-hydroxylase deficiency began in the 1950s. Glucocorticoid replacement therapy restores insufficient cortisol while suppressing excess ACTH, lowering adrenal androgen synthesis. Hydrocortisone is the ideal replacement for 21-OHD, 11 β -OHD, and 17 α -hydroxylase deficits due to its favorable physiologic profile and lower risk of side effects (Muthusamy *et al.* 2010).

The medicine is commonly provided orally in divided daily doses (10–20 mg/m²/day) to maintain steady hormone levels and decrease androgens. Families receive emergency injectable hydrocortisone kits (50 mg for youngsters and 100 mg for older people). In situations of poor response, doses may be increased to 20–30 mg/m²/day or switched to more potent, longer-acting synthetic glucocorticoids such as prednisone or dexamethasone; cautious titration is required to avoid overtreatment (Finkelstein *et al.* 2012).

CASE PRESENTATION

Here is a case presentation of 2-year-old child who presented in the emergency to Faisalabad Diabetic and Endocrinology Centre (F-DEC) with the symptoms of pubic hair (4 cm) growth over the last 7 days. Physical examination indicates an

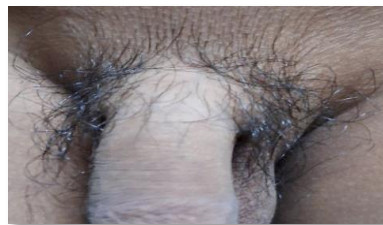

Fig. 1: Growth of pubic hairs (vellus hairs)

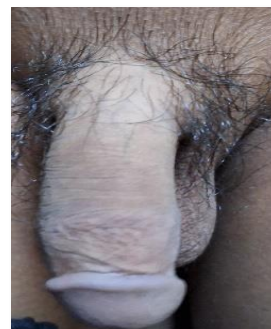


Fig. 2: Increased Penile Length

increased penile length of 7 cm that is too high according to his age, and this can be troublesome in the future, because the normal flaccid length in an adult male is 8.7 cm (Fig. 1–17). Clinical findings include the weight of the patient was 14 kg, height was 92 cm, and after laboratory analysis, the patient was diagnosed with non-classical congenital adrenal hyperplasia. There was no family history of any genetic cause; neither the father nor the mother had any disease. However, the mother had one miscarriage before this child during the first trimester, and the cause was unknown. The fetus showed no growth at all, which led to the miscarriage. About seven months later, the mother conceived again, and during the first month of pregnancy, she was given growth-supporting injections of Hydroxyprogesterone Caproate-Estradiol Valerate, four injections in total, administered once a week. This was considered an endangered pregnancy. The patient has eyesight issues, mental health was normal, he was socially active and there is growth of hair on the back of the patient. He was on hormonal therapy, taking Tab Hydrocortisone (10 mg) BD and some multivitamins.

DISCUSSION

Non-Classical Congenital Adrenal Hyperplasia (NCCAH) is a common autosomal recessive endocrine disorder resulting from partial 21-hydroxylase deficiency. Unlike the classical older children, point to early onset virilization, which can occur even in non-classical form if androgen levels are remarkably high. Such presentations are not common and often overlooked due to the milder nature of NCCAH compared to classical forms. The absence of family history

LH			
Test	Results	Unit	Reference Range
LH	0.36	mIU/mL	Male(20-70 years): 1.9 - 9.3 > 70 years: 3.1-34.6 Children: < 0.1-6 Infants(2-3 years): < 0.07 4-9 years: < 0.07-0.4 10-12 years: < 0.07-2.9 13-21 years: 1.0-7.1

Fig. 3: Showing an elevated level of luteinizing hormone in a patient than normal range

Chemistry		Verified On..... : 25/05/2023 11:20	
TEST	RESULTS	REFERENCE RANGE	
ACTH.....	64.8	pg/mL	7.2 - 63.3 pg/mL

Fig. 4: Showing elevated level of adreno-corticotropic hormone

Biochemistry Investigations			
Test	Results	Reference Range	Unit
Serum Calcium	9.8	8.5 - 10.0	mg/dl
Comments (if any): <i>Kindly correlate the results with other clinical investigations.</i>			

Fig. 5: Normal serum calcium level

Age: 2 Year(s)		Gender :	Male	Specimen Date: 24-May-2023 19:10
Referred By :		Sample :		Collected at PINUM.
Complete Blood Count (Blood CP)				
Test	Results	Reference Range	Unit	
WBC	6.0	4 - 11	10 ⁹ /L	
RBC	4.54	4.5 - 6.08	10 ¹² /L	
Hb	11.0	13 - 18	g/dL	
HCT	32.9	40 - 50	%	
MCV	72.5	79 - 93	fL	
MCH	24.2	25.5 - 32.2	pg	
MCHC	33.4	32.0 - 36.5	g/dL	
PLT	159	150 - 400	10 ⁹ /L	
MPV	11.0	6.5 - 11	fL	
Lymph%	62.7	20 - 45	%	
Neut%	28.2	40 - 70	%	
MID%	9.1	2 - 15	%	
Lymph#	3.8	1.2 - 3.6	10 ⁹ /L	
Neut#	1.7	1.5 - 6.5	10 ⁹ /L	
MID#	0.5	0.1 - 1.5	10 ⁹ /L	
RDW-CV%	14.0	11 - 16	%	
ESR	QNS	4 - 20	mm in 1st hour	
Comments (if any): <i>Kindly correlate the results with other clinical investigations.</i>				

Fig. 6: Complete blood count (CBC) analysis of the patient

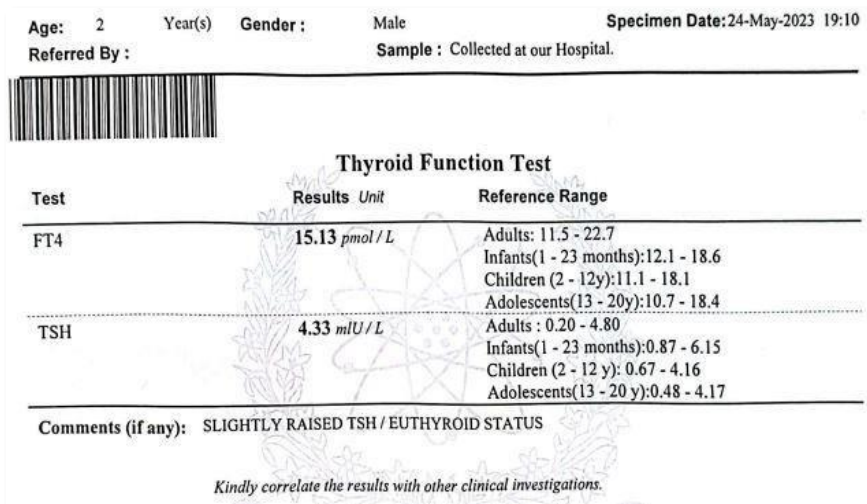


Fig. 7: Thyroid function test, indicating normal level of Free Thyroxin 4 (FT4) and milder elevated level of Thyroid Stimulating Hormone (TSH) in infants

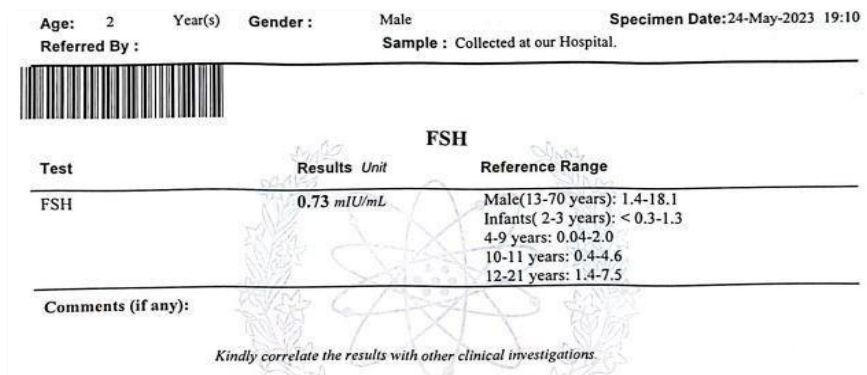


Fig. 8: Showing normal range of follicle stimulating hormone (FSH) in infants

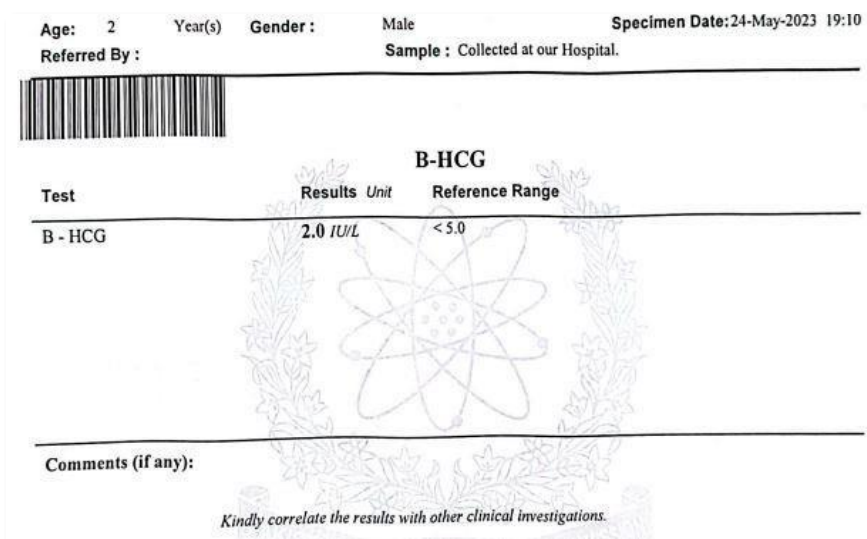


Fig. 9: Lab analysis showing normal value of Beta-human Chronic Gonadotropin in Patient

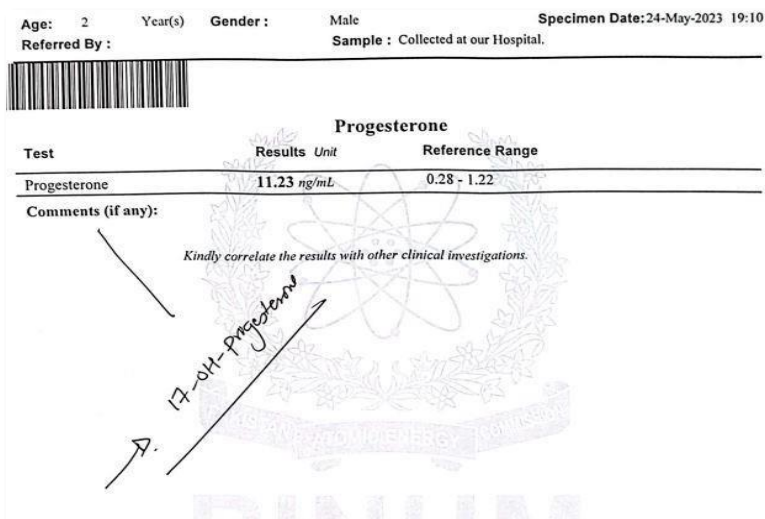


Fig. 10: Lab analysis shows an elevated level of progesterone analysis shows an elevated level of progesterone

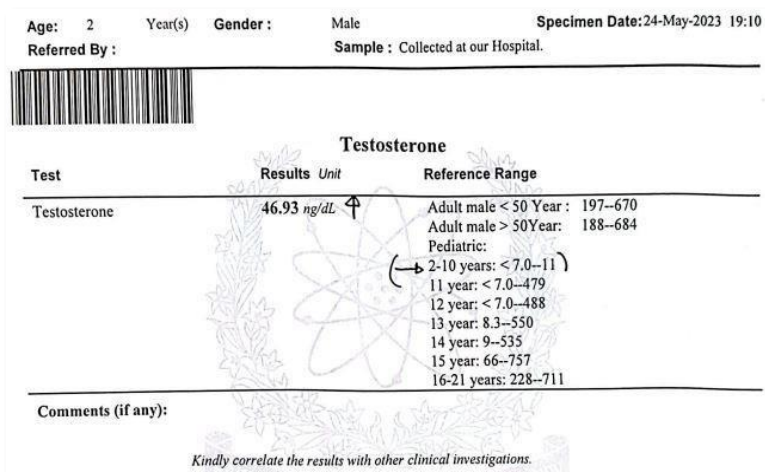


Fig. 11: Lab analysis shows an elevated level of testosterone

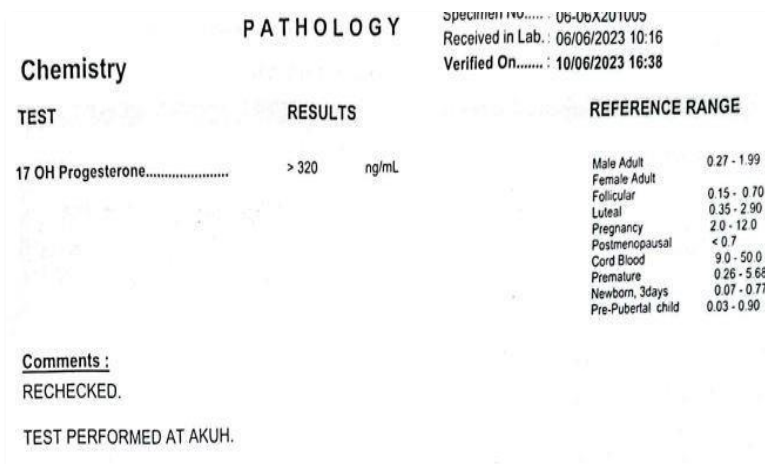


Fig. 12: Lab analysis shows an increased level of 17-hydroxy progesterone

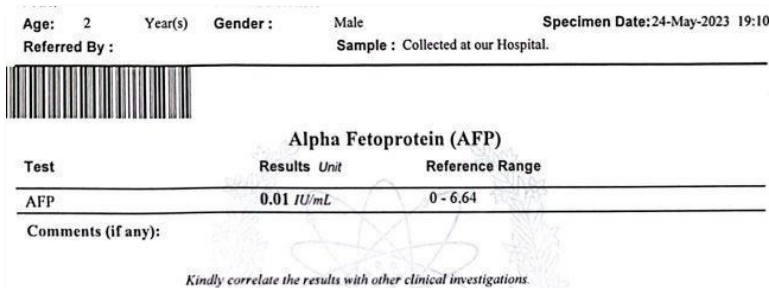


Fig. 13: Lab analysis shows normal level of alpha fetoprotein

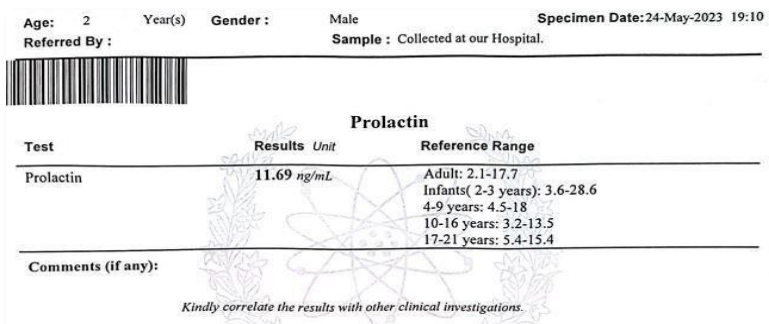


Fig. 14: Normal range of prolactin hormone in patient

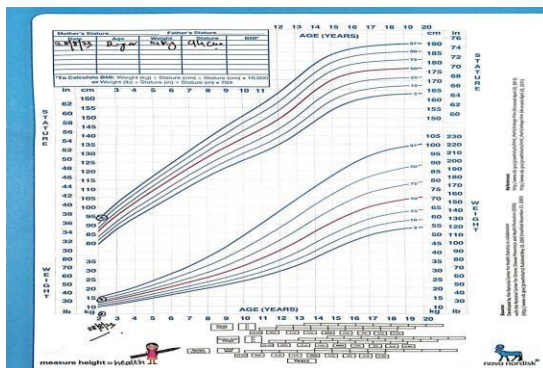


Fig. 15: Growth chart indicates height and weight relation

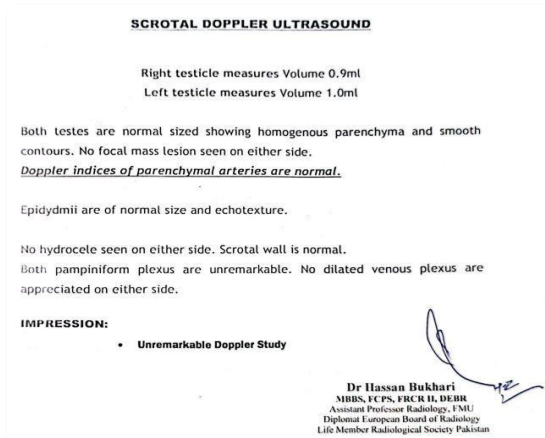


Fig. 16: Ultrasound report of the Scrotum region in the patient

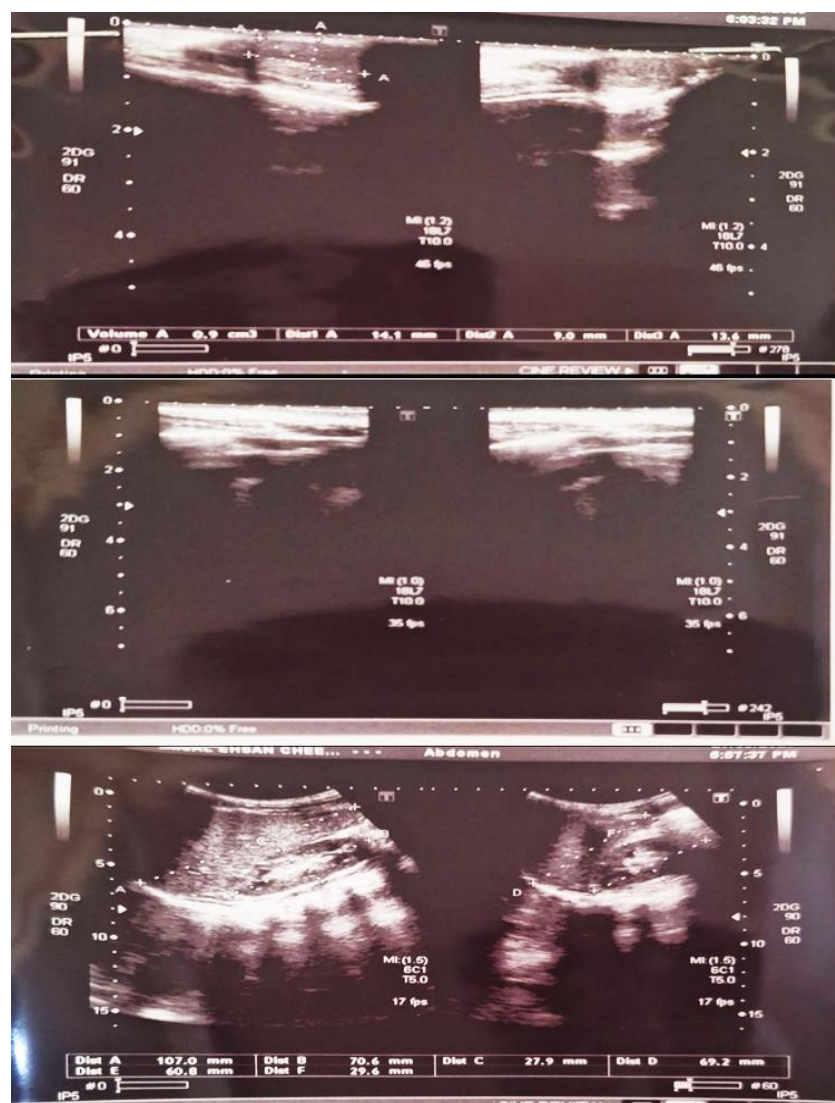


Fig. 17: Ultrasound image of the scrotum region in the patient

and the normal health status of both parents suggests a *de novo* carrier, indicating mutation or a recessive carrier state in one or both parents, which is consistent with an autosomal recessive inheritance pattern on CAH. The history of unexplained miscarriage in the first trimester may be coincidental, but it also raises the possibility of a previously affected fetus with a more severe phenotype or chromosomal abnormality (Finkielstein *et al.* 2012).

The administration of Hydroxyprogesterone Caproate and Estradiol Valerate during early pregnancy may have supported the gestation in this case, especially since it was labelled as an endangered pregnancy. However, there is limited evidence on whether these hormonal injections have any direct influence on fetal adrenal gland development. Elevated androgen levels in NCCAH result from partial 21-hydroxylase deficiency, leading to build-up of 17-OH progesterone and other precursors. In this case, early

hormonal therapy with hydrocortisone has been initiated, which is recommended as first-line treatment to reduce ACTH secretion and adrenal androgen production. The psychosocial and physical impact of such early symptoms can be significant; hence, timely diagnosis and management are crucial (Auer *et al.* 2023). This case highlights the importance of considering NCCAH in the differential diagnosis of premature pubarche, even in the absence of a family history. It also points out the role of detailed perinatal history and early endocrinology evaluation in patients presenting with signs of androgen excess (Auchus and Arlt 2013).

AUTHOR CONTRIBUTIONS

Noor Ul Ain designed and supervised the research and final draft of the manuscript; Fakhar Eman and Manahal Amjad completed the research, assisted in write-up, rephrasing, and

final draft preparation.

DATA AVAILABILITY

The data will be made available on a fair request.

ETHICS APPROVAL

Informed consent was obtained from the patient's family.

FUNDING SOURCE

This project is not funded by any agency.

REFERENCES

- Adriaansen BP, Schröder MA, Span PN, Sweep FC, van Herwaarden AE, Claahsen-van der Grinten HL (2022) Challenges in treatment of patients with non-classic congenital adrenal hyperplasia. *Frontiers in Endocrinology* 13: 1064024. <https://doi.org/10.3389/fendo.2022.1064024>.
- Auchus RJ, Arlt W (2013) Approach to the patient: the adult with congenital adrenal hyperplasia. *The Journal of Clinical Endocrinology & Metabolism* 98: 2645–2655. <https://doi.org/10.1210/jc.2013-1440>.
- Auer MK, Nordenström A, Lajic S, Reisch N (2023) Congenital adrenal hyperplasia. *Lancet* 401: 227–244. [https://doi.org/10.1016/S0140-6736\(22\)01330-7](https://doi.org/10.1016/S0140-6736(22)01330-7).
- Claahsen-van der Grinten HL, Speiser PW, Ahmed SF, Arlt W, Auchus RJ, Falhammar H, Flück CE, Guasti L, Huebner A, Kortmann BB (2022) Congenital adrenal hyperplasia—current insights in pathophysiology, diagnostics, and management. *Endocrine Reviews* 43: 91–159. <https://doi.org/10.1210/endrev/bnab016>.
- Finkelstein GP, Kim MS, Sinaii N, Nishitani M, Van Ryzin C, Hill SC, Reynolds JC, Hanna RM, Merke DP (2012) Clinical characteristics of a cohort of 244 patients with congenital adrenal hyperplasia. *The Journal of Clinical Endocrinology & Metabolism* 97: 4429–4438. <https://doi.org/10.1210/jc.2012-2102>.
- Kurtoğlu S, Hatipoğlu N (2017) Non-classical congenital adrenal hyperplasia in childhood. *Journal of Clinical Research in Pediatric Endocrinology* 9: 1–8. <https://doi.org/10.4274/jcrpe.3378>.
- Macut D, Zdravković V, Bjekić-Macut J, Mastorakos G, Pignatelli D (2019) Metabolic perspectives for non-classical congenital adrenal hyperplasia with relation to the classical form of the disease. *Frontiers in Endocrinology* 10: 681. <https://doi.org/10.3389/fendo.2019.00681>.
- Muthusamy K, Elamin MB, Smushkin G, Murad MH, Lampropulos JF, Elamin KB, Abu Elnour NO, Gallegos-Orozco JF, Fatourehchi MM, Agrwal N (2010) Adult height in patients with congenital adrenal hyperplasia: a systematic review and meta-analysis. *The Journal of Clinical Endocrinology & Metabolism* 95: 4161–4172. <https://doi.org/10.1210/jc.2009-2616>.
- Piróg M, Pulka A, Zabiegło E, Jach R (2024) Nonclassical congenital adrenal hyperplasia: Metabolic and hormonal profile. *Clinical Endocrinology* 100: 109–115. <https://doi.org/10.1111/cen.14988>.
- Podgórski R, Aebischer DA, Stompor M, Podgórska D, Mazur A (2018) Congenital adrenal hyperplasia: clinical symptoms and diagnostic methods. *Acta Biochimica Polonica* 65: 25–33. https://doi.org/10.18388/abp.2017_2343.